Cardiovasc Intervent Radiol (2024) 47:795–800
https://doi.org/10.1007/s00270-024-03669-1

CLINICAL INVESTIGATION MUSCULOSKELETAL INTERVENTIONS

Safety and Efficacy of Percutaneous Morton Neuroma Cryoneurolysis Under Ultrasound Guidance

Benjamin Moulin[1] · Giorgio Angelopoulos[1] · Jean Luc Sarrazin[1] · Stephane Romano[1] · Olivier Vignaux[1] · Thierry Guenoun[1] · Massimiliano Di Primio[1] · Antoine Hakime[1]

Received: 12 September 2023 / Accepted: 20 January 2024 / Published online: 4 March 2024
© Springer Science+Business Media, LLC, part of Springer Nature and the Cardiovascular and Interventional Radiological Society of Europe (CIRSE) 2024

Abstract

Purpose To assess the technical success, safety and early efficacy of Morton neuroma (MN) cryoneurolysis.

Materials and Methods Retrospective review of 54 consecutive patients with MN treated with cryoneurolysis after failure of conservative treatment, from September 2022 to June 2023. Outcomes measurements included technical success (defined a successful ultrasound-guided placement of the cryoprobe), procedural safety according to Cirse classification and change in 6 months post-procedure by pain numeric rating scale (pNRS).

Results A total of 59 MN were treated during 55 procedures. Mean procedure duration was 47 min, all patients were discharged 2 h after the intervention. Technical success was 98.1%. No Cirse grade 3, 4 or 5 complication was reported. Three grade 2 complication occurred, including two chilblain-type lesions and one bone insufficiency fracture. At 6 months post-procedure, pNRS score was significantly decreased (2.7 ± 2.2 vs 7.1 ± 1.1) ($p < 0.0001$), with a mean score decrease of 4.1points. Thirty-two patients (60.4%) reported a complete pain relief, 15 (28.3%) a partial pain relief and 6 (11.3%) no pain relief, or increased pain.

Conclusion Cryoneurolysis seems to be safe for the treatment of Morton neuroma. Six-month pain relief is promising and needs to be confirmed at long term.

✉ Benjamin Moulin
b.moulin00@gmail.com

[1] From the Interventional Radiology Unit, Imaging Department (B.M., G.A., J.L.S., O.V., M.D.P., A.H.), From the Orthopedic Surgery Unit (S.R), and From the Anesthesiology Department (TG), American Hospital of Paris, 55 Boulevard du Chateau, 92200 Neuilly-sur-Seine, France

Graphical Abstract

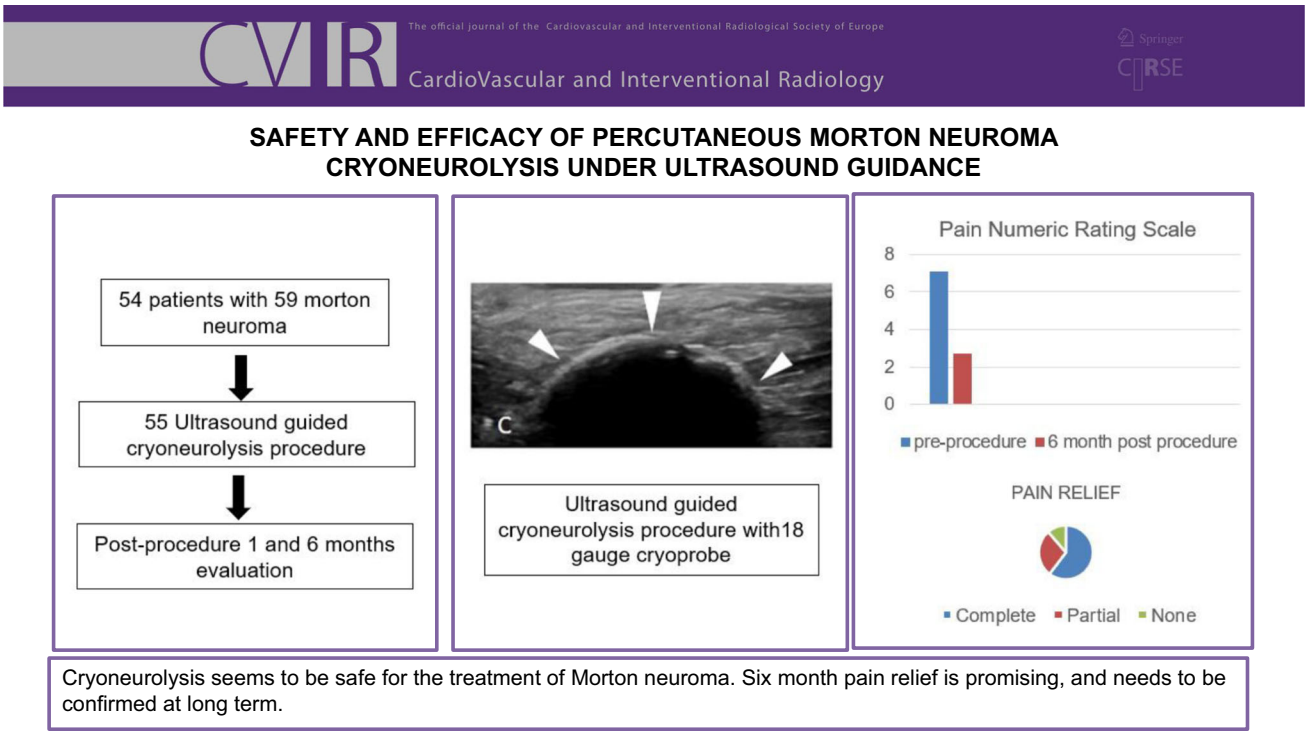

Keywords Morton neuroma · Metatarsalgia · Cryoneurolysis · Ultrasound guidance

Introduction

Morton's neuroma is a common painful condition affecting the intermetatarsal nerves of the foot [1]. It is characterized by the thickening of the nerve tissue, usually between the third and fourth metatarsal heads. Patients with Morton's neuroma often experience localized pain, numbness, tingling and a sensation of walking on a pebble. The condition significantly impairs the quality of life, limiting mobility and causing discomfort during regular activities [2]. Over the years, various treatment modalities have been explored to address the symptoms associated with Morton's neuroma. These treatment options range from conservative measures such as footwear modification, orthotic devices and steroid injections [3] to more invasive interventions like surgical excision [4]. Last twenty years, neurolysis, a procedure aimed at relieving nerve compression and promoting nerve regeneration, has emerged as a promising therapeutic approach. Different neurolysis techniques can be employed, including chemical neurolysis (also known as alcohol neurolysis [5]) and thermal neurolysis (radiofrequency [6] or cryoablation [7]). Cryoablation usually named cryoneurolysis when involving nerves consist of freezing the interdigital nerve to induce Wallerian degeneration. The use of extreme cold temperatures reduces the likelihood of thermal damage to surrounding healthy tissues and promotes faster recovery time. Additionally, ultrasound guidance provides precise control over the extent of the ice ball, to ensure of the global coverage of the neuroma. Due to its potential benefits and efficacy in the management of various chronic pain conditions, cryoneurolysis has been steadily increasing [8]. The purpose of this study is to report author's experience with cryoneurolysis for the treatment of Morton's neuroma.

Material and Methods

This retrospective observational single-center study obtained institutional board review approval. This review evaluates all consecutive patients treated by cryoneurolysis from October 2022 to March 2023.

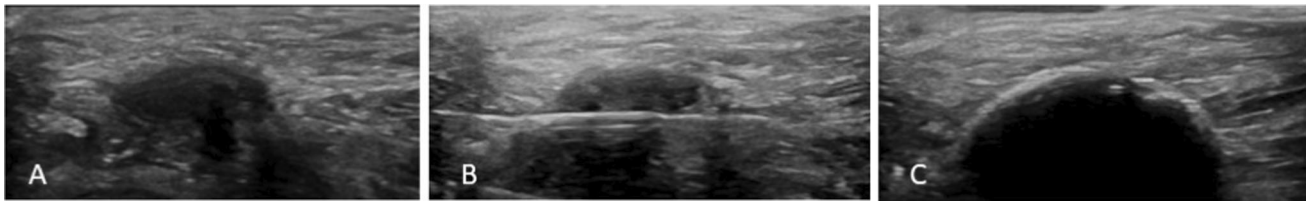

Fig. 1 Example of MN cryoneurolysis, ultrasound dorsal view. Image (**A**): hypoechogenic nodule on the intermetatarsal nerve in the third intermetatarsal space corresponding to MN. Image (**B**): cryoprobe positioned into the MN. Image (**C**): hyperechogenic ovoid image corresponding to the ice ball, covering the MN

Initial Evaluation

All patients were evaluated in pre-procedure clinical consultation, with documentation of pain numeric rating scale (pNRS) ranging from 0 to 10. Magnetic resonance imaging (MRI) of the forefoot was obtained within six weeks before the initial assessment for all patients. Decision to treat was based on clinical findings, including neuropathic pain of the second, the third or both intermetatarsal space, associated with a MN of at least 5 mm in diameter on MRI. All patients had previously experienced failure of a conservative treatment, including footwear modification, orthotic devices (foot pad) and steroid injections if accepted.

Cryoneurolysis Procedure

All procedures were performed in supine position under ultrasound guidance. General anesthesia, deep conscious sedation or local anesthesia was provided, at the discretion of the patient. Standard sterile technique was followed. First step of the procedure was local anesthesia, consisting of injection of long-acting amide local anesthetic agent (Ropivacaïne, 3 cc) with short-acting anesthetic agent (Lidocaïne, 3 cc) around the neuroma. This fluid injection also intended to protect surrounding tissue from thermal injury. Then, neuroma was punctured with a 17 gauge cryoprobe (Icesphere cryoprobe, Boston Scientifics) under US guidance, via an interdigital approach. Once the needle was positioned, cryoneurolysis was carried out. Time of freezing and number of cycle were dependent on the size of the neuroma and the extension of the ice ball, with at least two cycles of 1 min of freezing, without exceeding a total of two cycles of three minutes, at a power of 80% of the maximal freezing power. Endpoint of the procedure was full coverage of the MN by the ice ball at each cooling cycle. Patients were discharged after 2 h, on a day case basis. Weight bearing and walking were allowed the same day, but it was recommended to limit walking to a few steps for the first three days. No home nursing service, preventive anticoagulation or forefoot relief shoe was required. The resumption of driving was authorized after 7 days, and sporting activity after 4 weeks. Imaging features of cryoneurolysis procedure are presented in Fig. 1.

Clinical Follow-Up

Patients were followed up by telephone interviews at 4 weeks and 6 months after the procedure. Patients were asked to rate their pain recovery with the procedure, according to a three-point scale. Metrics evaluated also included pain numeric rating scale (pNRS) and complications, using the CIRSE classification. Patients without any pain or functional limitations were assessed only by phone. Others were offered a physical examination in the following days, to ensure the absence of severe complication. In case of suspicion of any late complication, persistent pain or late adverse event, an MRI of the forefoot was obtained.

Outcomes Measures

A retrospective review of the patients' medical records was performed to record sex, age, procedure duration, pre- and postoperative pNRS, postoperative hospitalization durations and complications.

Outcomes measurement were:

- Technical success based on the possibility to puncture and freeze the neuroma under US guidance
- Procedural safety based upon complications by Cirse complication classification [9]. Complications were reported for events that could be related to cryoneurolysis, and occurred either during the procedure or during the follow-up.
- Palliative effect of the procedure, by comparing pre-procedure pNRS score to pain reported 6 months post-procedure, and report of self-rating pain according to a three-point scale ("complete pain relief," "partial pain relief" and "no pain relief or increased pain").

Statistical Analysis

Statistical analysis was performed using statistical software EZR (Easy R) [10]. Continuous variables are expressed as means, standard deviations, ranges and dichotomous variables are expressed as frequencies and percentages when relevant. Wilcoxon signed-rank test was used for mean comparisons of paired parametric variables such as pNRS. *P* values less than 0.05 indicated statistical significance. Risk was fixed at 5%.

Results

Demographics

One patient did not complete the follow-up and was excluded from statistical analysis.

Fifty-four patients (45 women and 9 men) were included. Mean age was 49.1 ± 9.5 years. Fifty-five cryoneurolysis procedures were performed, including five procedures with treatment of two MN at the same time. There was a failed procedure under local anesthesia, subsequently retreated under conscious sedation with success, leading to a technical success of 98.1%. Mean procedure duration was 47 ± 22 min. Twenty-three procedures were carried out under local anesthesia (41.8%), 28 under conscious sedation (50.9%) and 4 under general anesthesia (7.2%).

Fifty-nine neuromas were treated. Mean size of the neuroma was 8.2 ± 1.8 millimeters. Fifty-one (86.4%) were MN of the third and 8 (13.6%) of the second intermetatarsal space.

All patients (54/54, 100%) were discharged two hours after the procedure.

Adverse Events

No major adverse event (Cirse grade IV or V) was observed.

Three grade II complications were observed (n = 2/53, 3.8%) including two chilblain-type lesions of distal third toe, and one bone insufficiency fracture of the third metatarsal, all managed with local treatment and oral analgesic therapy.

Seven grade I complications are observed, (n = 7/51, 13.2%) all consequently to persistent edema of the third intermetatarsal space requiring intermittent analgesic use. Among them, one presented with progressive onset of pain approximately 3 weeks after the intervention, with moderate local edema. Although the clinical situation suggested a complex regional pain syndrome, no according abnormality was seen in MRI and no vasomotor sudomotor or trophic signs were found.

Pain Outcomes

At 6 months post-procedure, 32 patients (60.4%) reported a complete pain relief, 15 (28.3%) a partial pain relief, and 6 (11.3%) no pain relief, or increased pain.

There was a significant difference between preoperative pNRS (mean 7.1 ± 1.1) and 6-month postoperative pNRS (mean 2.7 ± 2.2) ($p < 0.0001$), with a mean decrease of 4.1 ± 2.1 points.

Considering the five patients treated for two neuromas of intermetatarsal spaces 2 and 3 in a single session, only one patient had a satisfactory evolution, with pain relief.

Discussion

In this limited study, technical success of cryoneurolysis of MN was 98%. Only one procedure under local anesthesia was aborted early due to vagal syncope and successfully retreated under conscious sedation. These results corroborate those of the Cazzato study which, in a series of 20 patients, demonstrated the feasibility of percutaneous cryoneurolysis [7]. Two others studies [11, 12] reported results of MN cryoneurolysis with similar technical success.

No serious adverse events were reported in this study. Two patients presented a minor chilblain-type complication, resolutive in a few weeks with local treatment and oral nicardipine chlorhydrate therapy. The first was a diabetic patient, with distal arteriopathy and microvasculature disorders. The second patients had a Raynaud syndrome. Following these two episodes, we will refrain to perform cryoneurolysis on these patients.

Patients treated for two neuromas at the same time experienced poor pain release. Our hypothesis is that the coexistence in these patients of a mechanical disorder of the forefoot, in particular an insufficiency on the first ray, for which the absence of etiological treatment leads to poor results.

Additionally, one presented a bone insufficiency fracture on the third metatarsal which resolved spontaneously after 15 days of offloading. By comparison, surgical series also found significantly worse outcome in patients treated on multiple neuromas compared to single neuroma [13]. Consequently, authors also recommend not to treat two neuromas during the same session.

Many percutaneous neurolysis techniques have been described, including radiofrequency thermodestruction [6, 14, 15] and injections of ethanol [16]. All these techniques have demonstrated good feasibility with highly variable success rates, depending on the studies. Compared with these techniques, cryoneurolysis offers the advantage of being able to induce Wallerian degeneration with preservation of the peri- and epineurium, which is not an

irreversible damage. Consequently, the risk of occurrence of an amputation neuroma when the peri- and epineurium are preserved is minimal. In addition, the good visibility of the ice ball on ultrasound makes it possible to ensure more reproducible coverage of the neuroma, while limiting the risk of damage to surrounding structures. This is particularly true on the forefoot because of the possibility of monitoring the extension of the ice ball both in the axial and sagittal planes, and by the plantar or dorsal route. Finally, compared to other thermoablation techniques, cryoneurolysis can be performed under local anesthesia, which makes it an easily accessible technique.

The longer-term results of cryoneurolysis are still uncertain and need to be investigated. Cazzato et al. reported 77.7% of patients completely satisfied at 1 year. Other neurolysis procedures, like alcohol neurolysis, show a decrease in efficacy, with only 29% of patients symptom free at 5 years [5]. Comparatively, studies find higher success rates for surgical neurectomy, ranging from 51 to 85% in long-term follow-up studies [4, 13, 17–22]. On another hand, cryoneurolysis might offer an alternative to surgical approach with the advantages of avoiding the risk of amputation neuroma formation, shorter post-intervention recovery time and possibility to repeat procedure. Additionally, in case of failure, previous cryoneurolysis is not a contraindication to surgical therapy.

This study has limitations, including a small number of patients, the retrospective nature and the short follow-up duration, and must be assessed with caution, as these results need to be confirmed in the longer term. Questions remain unsolved concerning the selection of patients and the action to be taken in the event of partial success or failure of the intervention, and in particular the place of a possible second treatment session. Finally, surgical therapies and cryoneurolysis require comparative studies, including long-term series.

In conclusion, the results of this study support that treatment MN with cryoneurolysis is feasible, safe with low complication risk and encouraging early and midterm clinical results.

Acknowledgements None

Funding The authors state that this work has not received any funding.

Declarations

Conflict of interest The authors of this manuscript declare relationships with the following companies: B.M. disclosed no relevant relationships. G.A. disclosed no relevant relationships. J.L.S. activities related to the present article disclosed no relevant relationships. S.R. disclosed no relevant relationships. O.V. disclosed no relevant relationships. M.D.P. disclosed no relevant relationships. A.H. disclosed no relevant relationships.

Ethical Approval Institutional Review Board approval was obtained.

Informed Consent *Only if the study is on human subjects:* Written informed consent was obtained from all subjects (patients) in this study. Written informed consent was waived by the Institutional Review Board.

References

1. Hodes A, Umans H. Metatarsalgia. Radiol Clin North Am. 2018;56:877–92. https://doi.org/10.1016/j.rcl.2018.06.004.
2. Bhatia M, Thomson L. Morton's neuroma–current concepts review. Journal of Clinical Orthopaedics and Trauma. 2020;11:406–9. https://doi.org/10.1016/j.jcot.2020.03.024.
3. Hau MYT, Thomson L, Aujla R, et al. Medium-term results of corticosteroid injections for Morton's neuroma. Foot Ankle Int. 2021;42:464–8. https://doi.org/10.1177/1071100720966332.
4. Womack JW, Richardson DR, Murphy GA, et al. Long-term evaluation of interdigital neuroma treated by surgical excision. Foot Ankle Int. 2008;29:574–7. https://doi.org/10.3113/FAI.2008.0574.
5. Gurdezi S, White T, Ramesh P. Alcohol injection for Morton's neuroma: a five-year follow-up. Foot Ankle Int. 2013;34:1064–7. https://doi.org/10.1177/1071100713489555.
6. Chuter GSJ, Chua YP, Connell DA, Blackney MC. Ultrasound-guided radiofrequency ablation in the management of interdigital (Morton's) neuroma. Skeletal Radiol. 2013;42:107–11. https://doi.org/10.1007/s00256-012-1527-x.
7. Cazzato RL, Garnon J, Ramamurthy N, et al. Percutaneous MR-guided cryoablation of Morton's neuroma: rationale and technical details after the first 20 patients. Cardiovasc Intervent Radiol. 2016;39:1491–8. https://doi.org/10.1007/s00270-016-1365-7.
8. Ilfeld BM, Finneran JJ. Cryoneurolysis and percutaneous peripheral nerve stimulation to treat acute pain. Anesthesiology. 2020;133:1127–49. https://doi.org/10.1097/ALN.0000000000003532.
9. Filippiadis DK, Binkert C, Pellerin O, et al. Cirse quality assurance document and standards for classification of complications: the Cirse classification system. Cardiovasc Intervent Radiol. 2017;40:1141–6. https://doi.org/10.1007/s00270-017-1703-4.
10. Kanda Y. Investigation of the freely available easy-to-use software 'EZR' for medical statistics. Bone Marrow Transplant. 2013;48:452–8. https://doi.org/10.1038/bmt.2012.244.
11. Caporusso EF, Fallat LM, Savoy-Moore R. Cryogenic neuroablation for the treatment of lower extremity neuromas. J Foot Ankle Surg. 2002;41:286–90. https://doi.org/10.1016/S1067-2516(02)80046-1.
12. Friedman T, Richman D, Adler R. Sonographically guided Cryoneurolysis: preliminary experience and clinical outcomes. J Ultrasound Med. 2012;31:2025–34. https://doi.org/10.7863/jum.2012.31.12.2025.
13. Kasparek M, Schneider W. Surgical treatment of Morton's neuroma: clinical results after open excision. International Orthopaedics (SICOT). 2013;37:1857–61. https://doi.org/10.1007/s00264-013-2002-6.
14. Deniz S, Purtuloglu T, Tekindur S, et al. Ultrasound-guided pulsed radio frequency treatment in Morton's neuroma. J Am Podiatr Med Assoc. 2015;105:302–6. https://doi.org/10.7547/13-128.1.
15. Masala S, Cuzzolino A, Morini M, et al. Ultrasound-guided percutaneous radiofrequency for the treatment of Morton's neuroma. Cardiovasc Intervent Radiol. 2018;41:137–44. https://doi.org/10.1007/s00270-017-1786-y.

16. Hughes RJ, Ali K, Jones H, et al. Treatment of Morton's neuroma with alcohol injection under sonographic guidance: follow-up of 101 cases. Am J Roentgenol. 2007;188:1535–9. https://doi.org/10.2214/AJR.06.1463.
17. Bucknall V, Rutherford D, MacDonald D, et al. Outcomes following excision of Morton's interdigital neuroma: a prospective study. The Bone & Joint Journal. 2016;98:1376–81. https://doi.org/10.1302/0301-620X.98B10.37610.
18. Coughlin MJ, Pinsonneault T. Operative treatment of interdigital neuroma. A long-term follow-up study. J Bone Joint Surg Am. 2001;83:1321–8.
19. Faraj AA, Hosur A. The outcome after using two different approaches for excision of Morton's neuroma. Chin Med J (Engl). 2010;123:2195–8.
20. Giannini S, Bacchini P, Ceccarelli F, Vannini F. Interdigital neuroma: clinical examination and histopathologic results in 63 cases treated with excision. Foot Ankle Int. 2004;25:79–84. https://doi.org/10.1177/107110070402500208.
21. Nery C, Raduan F, Del Buono A, et al. Plantar approach for excision of a Morton neuroma: a long-term follow-up study. J Bone Joint Surg. 2012;94:654–8. https://doi.org/10.2106/JBJS.K.00122.
22. Pace A, Scammell B, Dhar S. The outcome of Morton's neurectomy in the treatment of metatarsalgia. International Orthopaedics (SICOT). 2010;34:511–5. https://doi.org/10.1007/s00264-009-0812-3.

Publisher's Note Springer Nature remains neutral with regard to jurisdictional claims in published maps and institutional affiliations.

Springer Nature or its licensor (e.g. a society or other partner) holds exclusive rights to this article under a publishing agreement with the author(s) or other rightsholder(s); author self-archiving of the accepted manuscript version of this article is solely governed by the terms of such publishing agreement and applicable law.